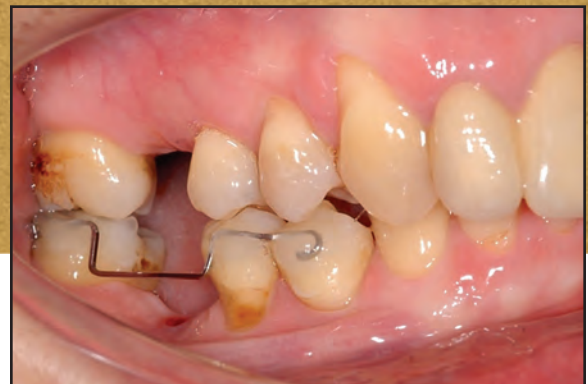
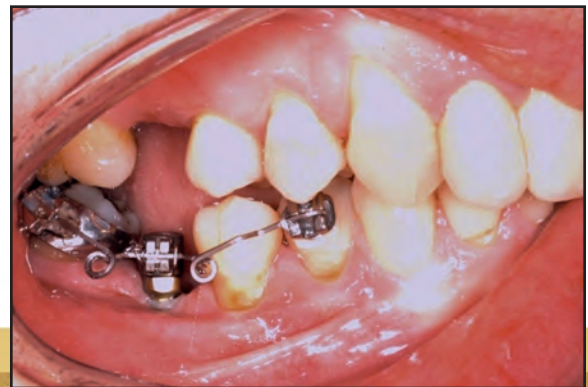
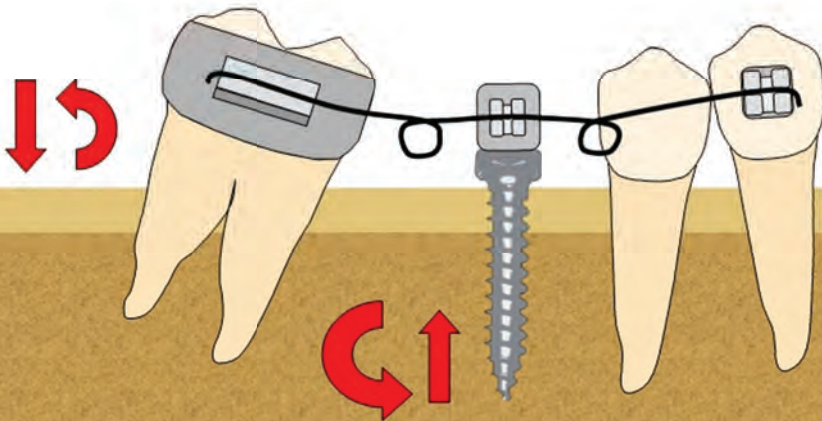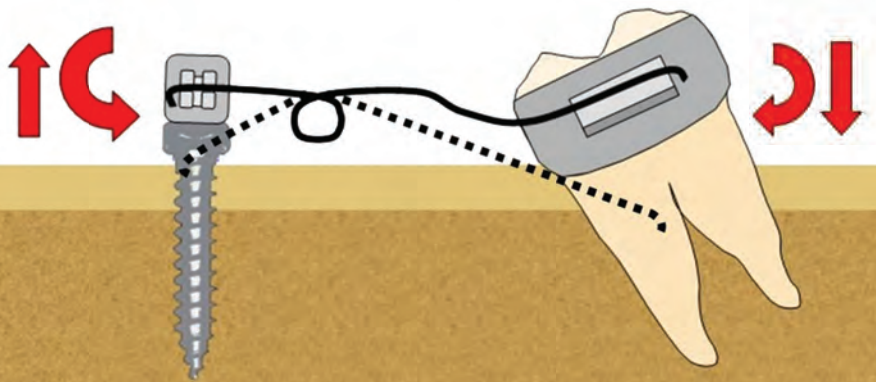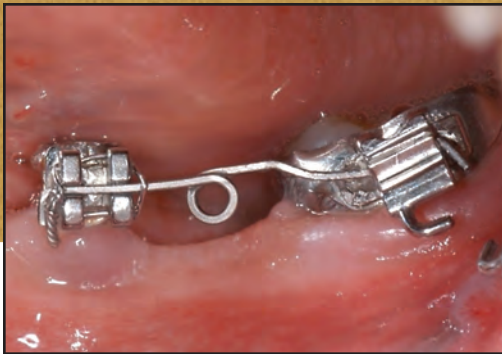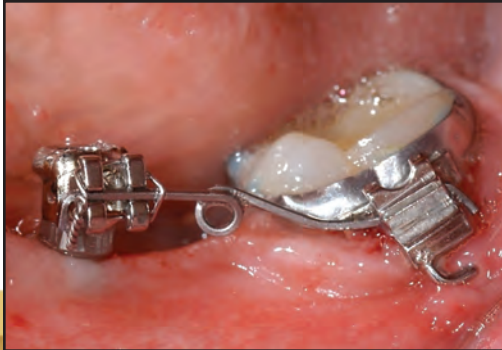Preprosthetic Molar Uprighting Using Skeletal Anchorage

MANUEL NIENKEMPER, DDS, MSC
ALEXANDER PAULS, DDS
BJÖRN LUDWIG, DMD, MSD
BENEDICT WILMES, DMD, MSD, PHD
DIETER DRESCHER, DMD, PHD

Unless a prosthetic replacement is inserted soon after extraction or loss of a first molar, the second molar may tip mesially into the edentulous space. Not only will the first-molar space contract mesiodistally, but eccentric occlusal loading will reduce the biomechanical loading capacity of the second molar.

Such a situation requires preprosthetic uprighing of the second molar using appropriate mechanics. Simply tipping the molar distally with a statically determined force system will lead to extrusion and likely cause occlusal interference. Therefore, a statically indeterminate system applying both an intrusive force and an uprighing moment of force would be preferable.¹ Stable anchorage is critical, since simultaneous intrusion and uprighing forces create a high moment load on the anchorage unit—a Class V geometry under the classification of Burstone and Koenig.^{2,3} Otherwise,

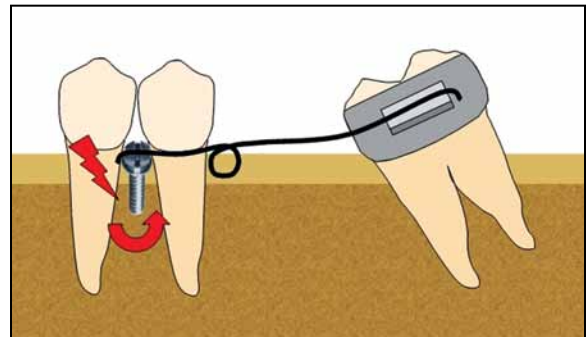


Fig. 1 Uprighting spring exerts axial moment on single buccal mini-implant, increasing risk of mini-implant failure.

unwanted mesial tipping and extrusion of the anchorage teeth may occur.

The use of an orthodontic mini-implant for direct anchorage can help avoid such dental side effects. However, an uprighing spring applies an axial moment to a screw inserted in the buccal segment, thus increasing the likelihood of implant failure⁴ (Fig. 1). This article describes an alterna-



Dr. Nienkemper



Dr. Pauls



Dr. Ludwig



Dr. Wilmes



Dr. Drescher

Dr. Nienkemper is an Instructor, Dr. Pauls is a researcher, Dr. Wilmes is an Associate Professor, and Dr. Drescher is Professor and Head, Department of Orthodontics, University of Düsseldorf, Moorenstrasse 5, 40225 Düsseldorf, Germany. Dr. Wilmes is also a Visiting Professor, Department of Orthodontics, University of Alabama at Birmingham School of Dentistry, and the developer of the Benefit system. Dr. Ludwig is a Contributing Editor of the *Journal of Clinical Orthodontics*; an Instructor, Department of Orthodontics, University of Homburg, Saar, Germany; and in the private practice of orthodontics in Traben-Trarbach, Germany. E-mail Dr. Nienkemper at nienkemm@web.de.

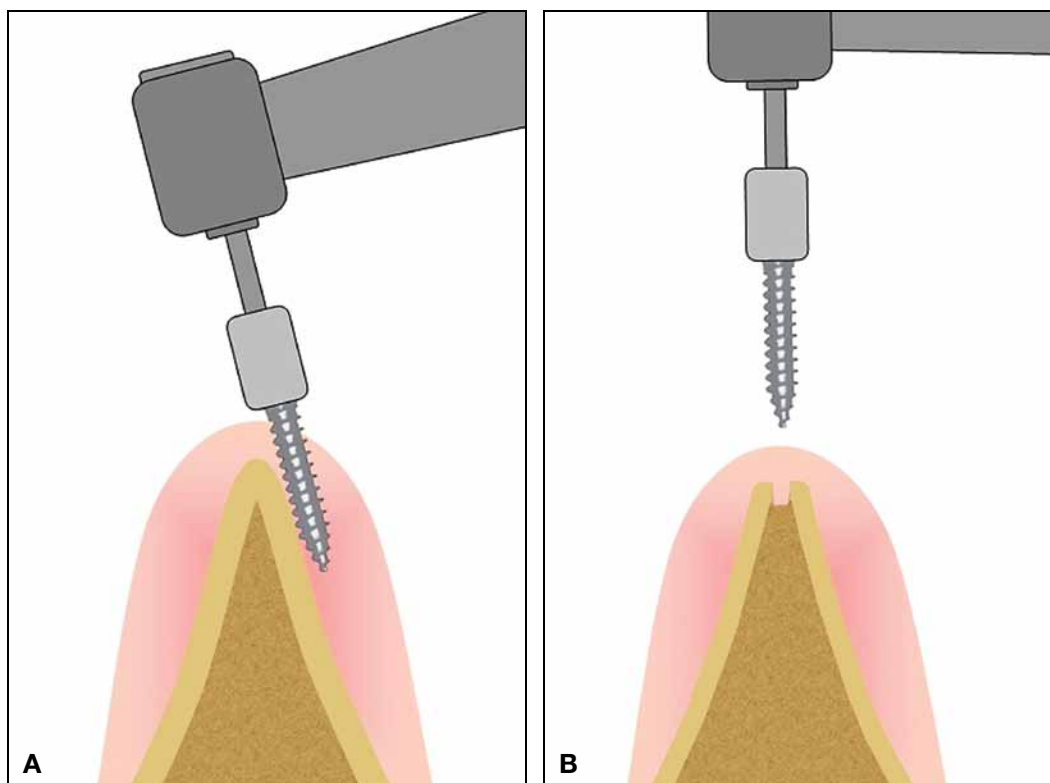


Fig. 2 Insertion of orthodontic mini-implant into narrow alveolar ridge in edentulous molar site. **A.** Without predrilling, mini-implant can easily slip laterally. **B.** Predrilling facilitates correct implant placement.

tive technique, using a mini-implant in an edentulous first-molar site as anchorage for uprighting a mesially tipped second molar.

Insertion Procedure

The mini-implant is inserted in the space of the missing first molar, perpendicular to the gingival surface. After a dental probe is used to locate the top of the atrophic alveolar crest and determine the best insertion site in terms of gingival thickness, the site is predrilled with a 1.4mm-diameter drill to a depth of about 3mm. Since the alveolar ridge is likely to have atrophied, predrilling will avoid lateral slippage of the mini-implant (Fig. 2).

A Benefit* mini-implant (2mm × 11mm) is inserted along the dental axis. The head of the Benefit screw has a special inner thread that allows

different kinds of abutments to be attached for various mechanics.⁵ In this case, an abutment with an .018" bracket is used.

The uprighting spring is bent from .016" × .022" TMA** wire and inserted between the bracket abutment of the mini-implant and the second-molar band. Activation with a mesial eccentric V-bend³ applies an uprighting moment and an intrusive force to the second molar (Fig. 3). A larger opposite moment and an extrusive force act on the mini-implant. To counteract the buccal tipping moment created by the intrusive force, additional buccal root torque may be applied.

*PSM Medical Solutions, Tuttlingen, Germany; www.psm.ms. PSM North America, Inc., Indio, CA; www.psm-na.us.

**Registered trademark of Ormco Corporation, Orange, CA; www.ormco.com.

Case 1

A 45-year-old female presented with a mesially tipped lower left second molar following previous extraction of the first molar and second premolar. A Benefit mini-implant was inserted into the alveolar ridge, and an uprighting spring was placed and activated according to the procedure described above (Fig. 4A).

Five months later, the lower second molar had been uprighted without any extrusion (Fig. 4B). The mini-implant remained stable throughout treatment and was subsequently used to anchor a temporary crown that would prevent overeruption of the upper dentition.

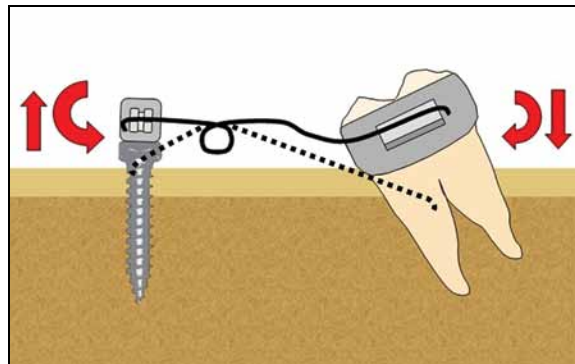


Fig. 3 Uprighting spring activated with mesial eccentric V-bend.

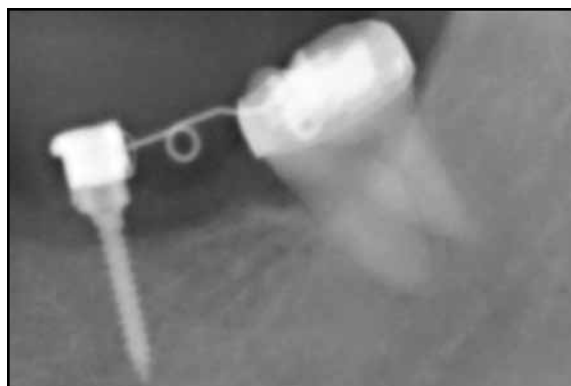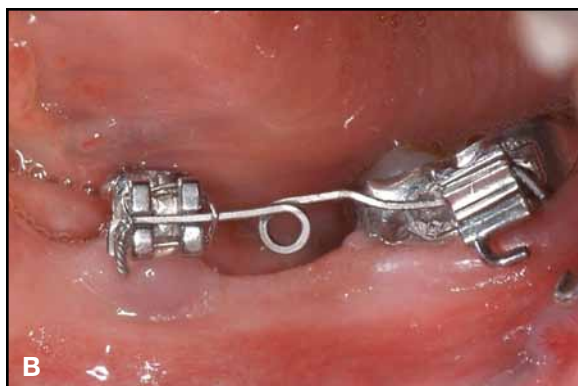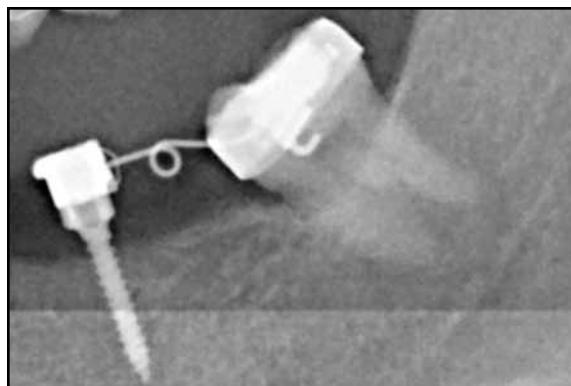


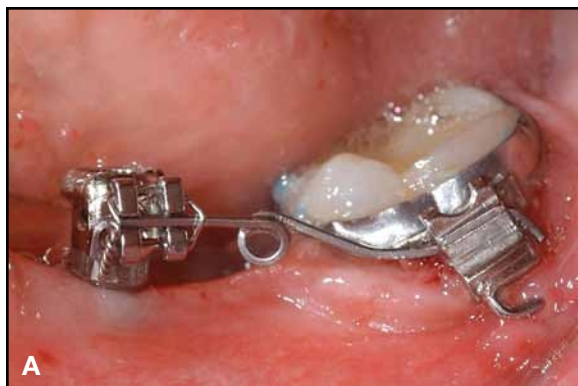Fig. 4 Case 1. 45-year-old female patient with missing lower left second premolar and first molar and mesially tipped lower left second molar. **A.** Benefit* mini-implant with bracket abutment placed in alveolar ridge for attachment of uprighting spring. **B.** After five months of molar-uprighting treatment without any extrusion.

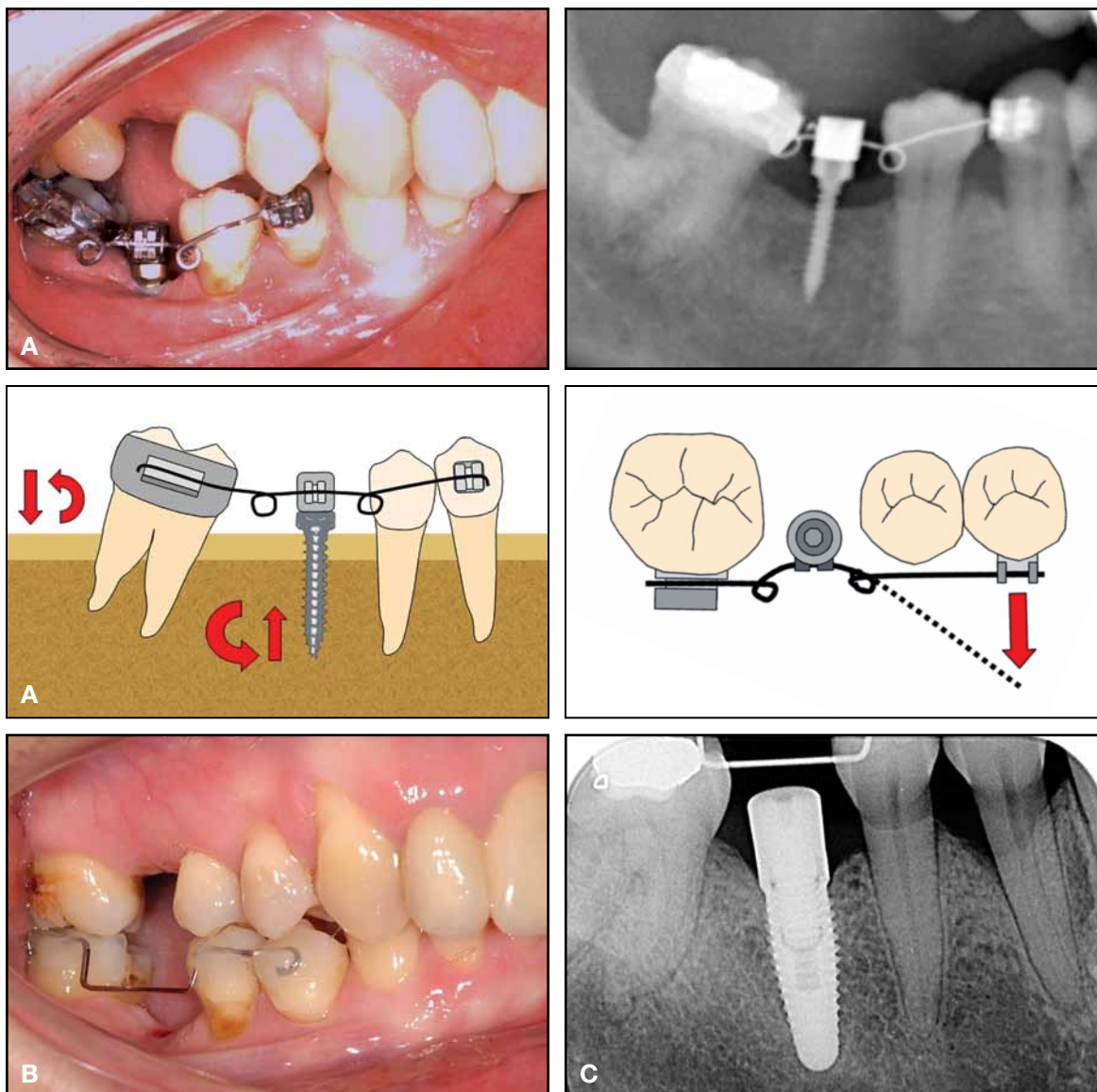


Fig. 5 Case 2. 51-year-old female patient with mesially tipped lower right second molar and lingually displaced lower right first premolar. A. After insertion of Benefit mini-implant with bracket abutment in alveolar ridge, sectional wire extended distally for second-molar uprighting and mesially for buccal movement of first premolar. B. After seven months of molar-uprighting treatment without extrusion, buccal wire bonded for retention. Note improved occlusion of first premolar due to buccal movement. C. Dental implant in first-molar site.

Case 2

A 51-year-old female was referred by her general dentist for preprosthetic treatment. Her lower right first molar had been extracted several years earlier, and the second molar was tipped mesially into its space. Although the patient had a severe Class II malocclusion with a deep bite, she refused comprehensive orthodontic treatment.

After insertion of a Benefit mini-implant in the alveolar ridge, a sectional wire was inserted and activated as in Case 1. Because the lower right first premolar was lingually displaced, the mesial segment of the sectional wire was extended to the bracketed first premolar and activated to produce buccal movement (Fig. 5A).

Seven months later, the second molar had been uprighted without extrusion, and the occlusion of the first premolar had been improved. A fixed retainer was placed to stabilize the buccal segment until prosthetic treatment was finished (Fig. 5B,C).

Discussion

Controlled molar uprighting without extrusion is a major challenge for the orthodontist. TMA uprighting springs that are activated as recommended by Burstone and Koenig apply both an uprighting moment and an intrusive force,⁶ but also apply a significant moment to the anchorage unit. Skeletal anchorage can solve this problem.

Optimum stability is achieved by inserting a larger-diameter mini-implant into the alveolar ridge, safely away from the dental roots.⁷⁻¹³ If the mini-implant is placed buccally, however, the uprighting spring will produce an axial moment that increases the risk of miniscrew failure (Fig. 1). Using two buccal mini-implants or employing indirect skeletal anchorage would be possible alternatives, but the latter option can cause unwanted tooth movement.

As demonstrated by the two cases shown here, insertion of a mini-implant into the alveolar ridge of an edentulous first-molar site can provide stable anchorage for second-molar uprighting with an effective uprighting spring. Controlled tooth movement is achieved without extrusion, and the direct anchorage avoids undesirable dental side effects.

Because the alveolar bone of an edentulous molar site has usually atrophied, inserting a mini-implant into the tapered crestal bone without predrilling would risk lateral slippage of the screw.¹⁴ An oral surgeon usually places a dental implant under direct view by raising a surgical flap and then flattening the bone surface. Since direct access is not feasible during transgingival insertion of an orthodontic mini-implant, predrilling can create a kind of funnel to guide the mini-implant tip, ensuring stable placement.

REFERENCES

- Weiland, F.J.; Bantleon, H.P.; and Droschl, H.: Molar uprighting with crossed tipback springs, *J. Clin. Orthod.* 26:335-337, 1992.
- Drescher, D.; Bourauel, C.; and Their, M.: [A pseudoelastic NiTi uprighting spring for the molars—Its design, biomechanical testing and clinical use], *Fortschr. Kieferorthop.* 53:286-296, 1992.
- Burstone, C.J. and Koenig, H.A.: Force systems from an ideal arch, *Am. J. Orthod.* 65:270-289, 1974.
- Park, H.S.; Jeong, S.H.; and Kwon, O.W.: Factors affecting the clinical success of screw implants used as orthodontic anchorage, *Am. J. Orthod.* 130:18-25, 2006.
- Wilmes, B. and Drescher, D.: A miniscrew system with interchangeable abutments, *J. Clin. Orthod.* 42:574-580, 2008.
- Drescher, D.; Bourauel, C.; and Their, M.: Application of the orthodontic measurement and simulation system (OMSS) in orthodontics, *Eur. J. Orthod.* 13:169-178, 1991.
- Wilmes, B.; Rademacher, C.; Olthoff, G.; and Drescher, D.: Parameters affecting primary stability of orthodontic mini-implants, *J. Orofac. Orthop.* 67:162-174, 2006.
- Miyawaki, S.; Koyama, I.; Inoue, M.; Mishima, K.; Sugahara, T.; and Takano-Yamamoto, T.: Factors associated with the stability of titanium screws placed in the posterior region for orthodontic anchorage, *Am. J. Orthod.* 124:373-378, 2003.
- Wiechmann, D.; Meyer, U.; and Buchter, A.: Success rate of mini- and micro-implants used for orthodontic anchorage: A prospective clinical study, *Clin. Oral Impl. Res.* 18:263-267, 2007.
- Chen, C.H.; Chang, C.S.; Hsieh, C.H.; Tseng, Y.C.; Shen, Y.S.; Huang, I.Y.; Yang, C.F.; and Chen, C.M.: The use of micro-implants in orthodontic anchorage, *J. Oral Maxillofac. Surg.* 64:1209-1213, 2006.
- Chen, Y.H.; Chang, H.H.; Chen, Y.J.; Lee, D.; Chiang, H.H.; and Yao, C.C.: Root contact during insertion of miniscrews for orthodontic anchorage increases the failure rate: An animal study, *Clin. Oral Impl. Res.* 19:99-106, 2008.
- Kuroda, S.; Yamada, K.; Deguchi, T.; Hashimoto, T.; Kyung, H.M.; and Takano-Yamamoto, T.: Root proximity is a major factor for screw failure in orthodontic anchorage, *Am. J. Orthod.* 131(4 suppl.):68-73, 2007.
- Wilmes, B.; Ottenstreuer, S.; Su, Y.Y.; and Drescher, D.: Impact of implant design on primary stability of orthodontic mini-implants, *J. Orofac. Orthop.* 69:42-50, 2008.
- Kravitz, N.D. and Kusnoto, B.: Risks and complications of orthodontic miniscrews, *Am. J. Orthod.* 131(4 suppl.):43-51, 2007.